

Functional MRI as a tool for assessing chiasmal visual defect in a patient with neuromyelitis optica

Bitemporal haemianopsia is the classic visual field defect of disorders that involve the optic chiasm, caused by the involvement of the crossing nasal–retinal fibres of each optic nerve. Chiasmal visual field defects are usually categorised as extrinsic because of mechanical compression from adjacent structures, although lesions involving the substance of the chiasm itself also exist.¹

We describe a unique case of chiasmal neuritis, a woman with serologically proven neuromyelitis optica (NMO).² Our study addresses the temporal consequences of this acquired bitemporal haemianopsia. Functional MRI (fMRI) was used to evaluate the cortical activation patterns and its

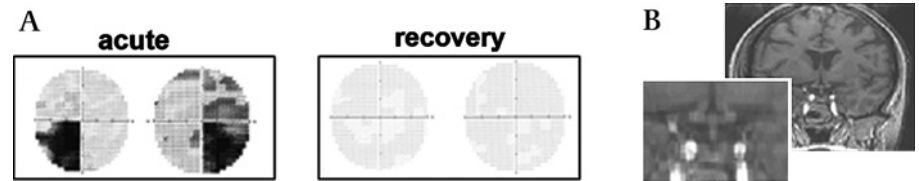


Figure 1 (A) Visual fields during the acute phase (left) and subsequent recovery (right). (B) Coronal T1-weighted MRI during the acute phase (the optic chiasm is shown in the blow-up view).

correspondence with visual field representation during the attack and subsequent recovery.

A 36-year-old woman presented with acute bilateral visual loss progressing during several days before her admission. Her history included serologically positive myasthenia gravis at the age of 10 years, which required immunosuppressive treatment that led to clinical remission and cessation of all drug treatment at age 13 years. She was

asymptomatic until age 26 years, when she presented with an episode of transverse myelitis. Since then, she has had another three severe myelitic episodes, without optic nerve involvement and was, therefore, under maintained treatment of prednisone and cyclophosphamide. Six months before her current admission, she was tested positive for NMO-immunoglobulin.² To note is that her daily cyclophosphamide dosage was reduced just before her current admission.

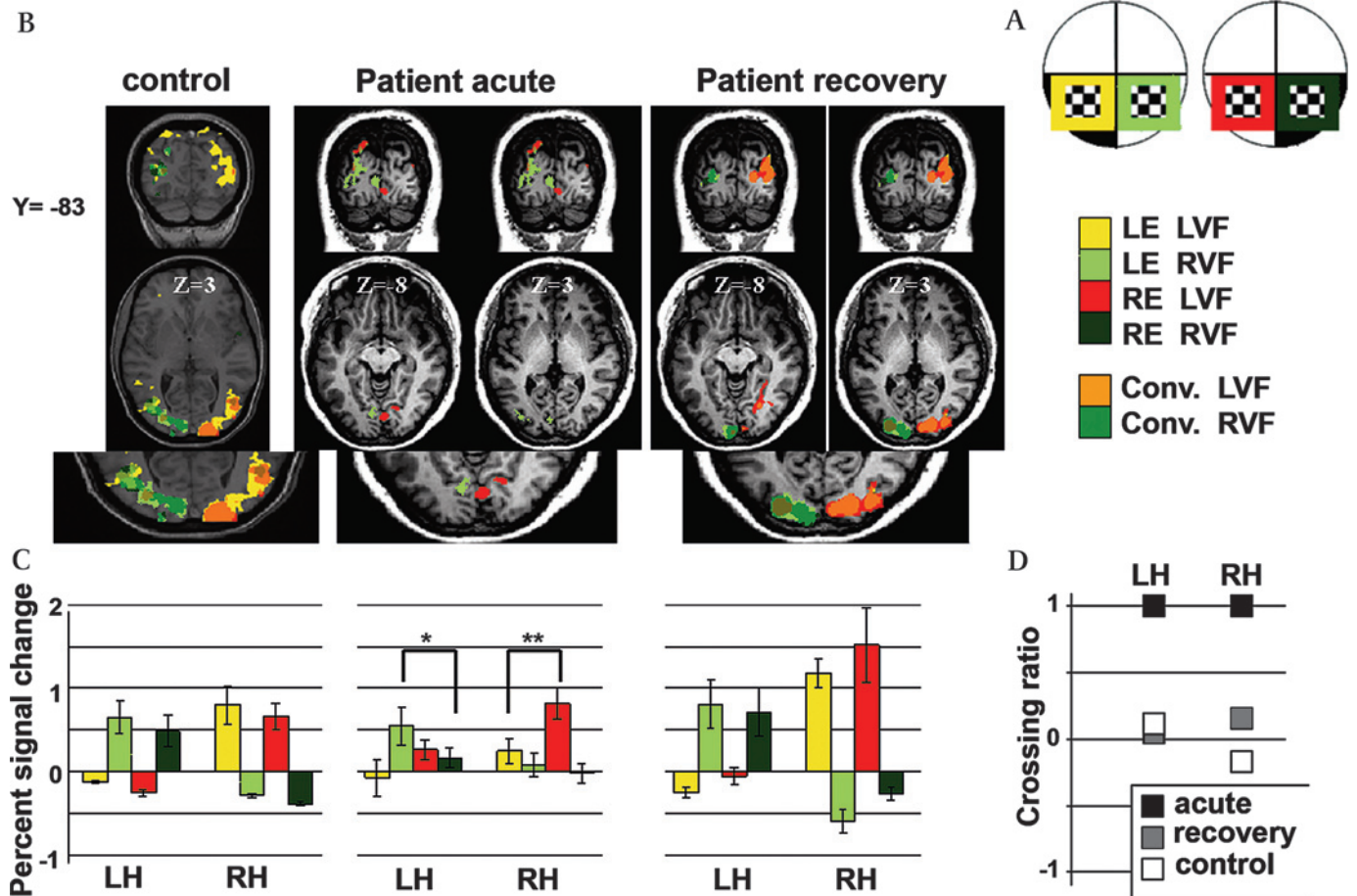


Figure 2 (A) Experimental design. Four experimental conditions were used: (1) stimuli projected to the LVF via the LE, marked in yellow; (2) stimuli projected to the RVF via the LE, marked in light green; (3) stimuli projected to the LVF via the RE, marked in red; (4) stimuli projected to the RVF via the RE, marked in dark green. LE, left eye; LVF, left visual field; RE, right eye; RVF, right visual field. (B) Coronal and axial views of the fMRI activation patterns, elicited during the four experimental conditions. Activation is shown for the posterior occipital cortex for a control participant (left) and for the patient during acute phase (middle) and after recovery (right panel). Same colours as in C (see scale). *Conv.* (convergence) refers to the overlap of activation elicited by stimuli projected to both eyes. (C) Average activation level (per cent signal change) histograms. Activation levels during stimuli presentation in V1, showing the relative contribution of all experimental conditions (see Supplementary Methods for details). The asterisks denote significance level, paired *t* test: LH $P < 0.05$; RH $P < 0.01$. (D) Crossing ratio. Assessment of the relative contribution of the ipsilateral and contralateral eyes for activating V1 in each hemisphere (see Supplementary Methods for details).

Her clinical examination revealed a parapyramidal syndrome with sensory level at T5 and mild left optic disc temporal pallor. No relative afferent pupillary defect was detected. Snellen visual acuity measurements were 6/60 in the right eye and 6/9 in the left eye. The Humphrey perimetry visual field test (10-2 threshold) demonstrated bitemporal defects, which were more pronounced in the lower visual field (figure 1A). T1-, T2- and fluid attenuation inversion recovery-weighted MRI were performed in the acute phase. Several periventricular white matter lesions were evident with no detectable optic chiasm abnormality (figure 1B). The patient was treated with intravenous steroids followed by a decrementing dose of oral prednisone. Full cessation of symptoms was reported 2 months after the attack.

To further assess her bitemporal haemianopsia, an fMRI experiment was performed. During the fMRI scan, a flickering checkerboard was projected separately to each eye in each visual field (figure 2A). Stimuli were projected to the lower visual fields and were designed to fall within the scotoma of the patient when projected to her blind fields.¹ This paradigm was carried out twice: (1) During the acute phase and (b) after visual recovery (8 months afterwards). The same paradigm was performed on a control participant matched for age and sex. In addition, a conventional retinotopic mapping was performed. The fMRI measurements were performed in a 3 T Siemens Trio scanner.

In intact visual pathways, each hemisphere receives information from both eyes. Information projected on the ipsilateral eye is carried by the non-crossing temporal-retinal fibres; information projected on the contralateral eye is carried by the crossing nasal-retinal fibres. Binocular activations in each hemisphere were demonstrated in the control participant (figure 2B, C). We assumed that in the presence of chiasmal damage, information carried by the nasal-retinal fibres, normally crossing through the optic chiasm, would not reach the lateral geniculate nucleus and the primary visual cortex. Indeed, during the acute phase, visual cortical areas were activated only monocularly by stimuli projected to the ipsilateral eye. Recovery was associated with the return of binocular activation in each hemisphere, corresponding to the renewal of nasal-retinal fibres' projections. These results can be observed in the cortical activation maps (figure 2B) and in the averaged activation level in V1 (figure 2C).

Figure 2D presents quantitative assessment of the relative projections of each eye to each hemisphere. This was calculated in

the left and right hemispheres separately using the following crossing ratio³:

$$= \frac{\text{Activation}_{\text{ipsilateral eye}} - \text{Activation}_{\text{contralateral eye}}}{\text{Activation}_{\text{ipsilateral eye}} + \text{Activation}_{\text{contralateral eye}}}$$

Within V1, crossing ratios during the acute phase equalled 1 for both left (LH) and right hemispheres (RH), demonstrating the exclusive uncrossed activations (elicited by the ipsilateral eye via the temporal fibres). Conversely, crossing ratios after recovery and in the control participant were close to zero, indicating the similar crossed and uncrossed activations (patient at recovery 0.04 and 0.15; control participant 0.12 and -0.17 for the LH and the RH, respectively). Similar results were obtained when analysing the crossing ratio in the entire retinotopic areas (acute phase 1.00 and 1.00; recovery phase -0.09 and 0.12; control participant -0.01 and -0.16, for the LH and the RH, respectively).

This study describes a unique case of serologically proven NMO with chiasmal neuritis. We used fMRI to assess the cortical consequences of acquired bitemporal haemianopsia, looking at the activation levels of acute versus recovery phases. We demonstrated that during the acute phase of chiasmal neuritis, visual cortical areas were activated only monocularly, whereas recovery was associated with the return of normal binocular input. These results confirm the association between bitemporal haemianopsia and an ipsilateral-only projection of the retinogeniculate pathway.

fMRI had a major impact on cognitive neuroscience, and its ability to demonstrate a function-structure relationship in healthy volunteers has been demonstrated clearly in the visual system. However, it is still in its earliest stages of transition from research laboratories to clinical application.

The cortical consequence of chiasmal abnormalities had previously been limited to congenital abnormalities as in an achiasmatic patient, in whom each eye projects to the ipsilateral hemisphere,⁴ and in albinos, in whom most of the retinal ganglion cells cross to the contralateral side.^{3, 5} Our study, however, described the cortical consequences of acquired (adult) bitemporal haemianopsia, in which the nasal-retinal fibres are temporarily lost rather than misrouted. We demonstrated the outcome of damage and recovery to the optic chiasm formation.

This study illustrates the benefit of adding fMRI to standard anatomical scans. We, therefore, recommend using fMRI as a clinical tool for studying the neurological basis of unclear visual field impairments.

N Raz,¹ A Vaknin,¹ S Chokron,² T Ben-Hur,¹ N Levin¹

¹Department of Neurology, Hadassah Hebrew University Hospital, Jerusalem, Israel; ²Service de Neurologie, Fondation Ophtalmologique Rothschild, Paris, France

Correspondence to Dr Noa Raz, Department of Neurology, Hadassah Hebrew University Hospital, Jerusalem, Israel; noa.raz@mail.huji.ac.il

Funding This study was funded by the Caesarea Edmond & Benjamin de Rothschild Foundation and by research grants.

Competing interests None.

Patient consent Obtained.

Ethics approval This study was conducted with ethics approval provided by the Hadassah Hebrew University Medical Center ethics committee.

Provenance and peer review Not commissioned; externally peer reviewed.

Received 16 May 2009

Revised 22 July 2009

Accepted 9 August 2009

Published Online First 22 August 2010

J Neurol Neurosurg Psychiatry 2010;**81**:1174-1175.
doi:10.1136/jnnp.2009.183749

REFERENCES

1. **Foroozan R.** Chiasmal syndromes. *Curr Opin Ophthalmol* 2003;**14**:325-31.
2. **Wingerchuk DM, Lennon VA, Pittock SJ, et al.** Revised diagnostic criteria for neuromyelitis optica. *Neurology* 2006;**66**:1485-9.
3. **Schmitz B, Käsmann-Kellner B, Schäfer T, et al.** Monocular visual activation patterns in albinism as revealed by functional magnetic resonance imaging. *Hum Brain Mapp* 2004;**23**:40-52.
4. **Victor JD, Apkarian P, Hirsch J, et al.** Visual function and brain organization in non-decussating retinal-fugal fibre syndrome. *Cereb Cortex* 2000;**10**:2-22.
5. **Hoffmann MB, Tolhurst DJ, Moore AT, et al.** Organization of the visual cortex in human albinism. *J Neurosci* 2003;**23**:8921-30.

Activated microglia in the subthalamic nucleus in hyperglycaemic hemiballism: a case report

Non-ketotic hyperglycaemia is one of the causes of hemiballism.^{1, 2} The involuntary movement is also sometimes referred to as hemichorea. Hyperglycaemic hemiballism has been thought to occur in patients with poorly controlled diabetes. MRI usually shows a hyperintense lesion of the contralateral basal ganglia in T1-weighted image.³ Although there have been a few pathological studies of hyperglycaemic hemiballism, no studies have shown pathological alteration in the subthalamic nucleus (corpus Luysii) which is responsible for the hemiballism resulting from ischaemia.⁴ Originally, Schwarz and Barrows reported hyperglycaemic hemiballism as 'hemiballism without involvement of Luys' body.'² We herein report a case of hyperglycaemic hemiballism in which immunohistochemistry showed the presence of activated microglia in the subthalamic nucleus contralateral to the hemiballism.

¹fMRI acquisition parameters and detailed description of the experimental design and the data analysis are described in the Supplementary Methods.